Dressings 145

Afsaneh Alavi, Hadar Lev-Tov and Robert S. Kirsner

Chapter Contents

Moist Healing Environment 2501
History of Wound Dressings 2501
Functions of a Wound Dressing 2501
Traditional Wound Dressings 2502
First and Second Intention Healing 2502
Role of Debridement 2503
Wound Cleansers 2503
Topical Antimicrobials and Dressings that Contain Antimicrobial Agents 2503
Moisture-Retentive Dressings 2505
Advanced Wound Therapies 2510
Compression Therapy 2514
Future Directions 2515

Key features

- Wound dressings have evolved from simple wound coverings to more active wound management tools that directly interact with the wound environment
- No perfect dressing exists for all wounds but when used appropriately, dressings can improve healing time and cosmesis as well as reduce pain and infections
- Semipermeable or occlusive dressings provide a moist environment, retain wound fluid that contains growth factors conducive to healing, and promote a low tissue oxygen tension that stimulates angiogenesis and deposition of collagen
- The major types of moisture-retentive dressings include films, foams, hydrogels, alginates, gelling fibers, hydrocolloids, and superabsorbents

INTRODUCTION

Dermatologists are involved in the care of a variety of acute and chronic wounds including surgical incisions. The range of treatment options is substantial and expanding, providing therapeutic flexibility. Appropriate wound dressing selection requires an understanding of the properties of various dressings, as well as their advantages and disadvantages. As the wound heals, the ideal dressing may change based on the amount of exudate, necrotic tissue, and pain or the presence or absence of infection (Table 145.1).

MOIST HEALING ENVIRONMENT

Providing a moist wound environment is an important principle of wound healing. There are several mechanisms by which moisture assists the healing process, the most basic of which is reduced tissue desiccation and prevention of crust formation. Studies by Winter[1] demonstrated that uncovered, air-dried wounds re-epithelialized at a slower rate (see below). This slower rate has been attributed to the requirement of the regenerating epidermis to migrate below an overlying crust and other dry fibrous tissue to a region of moisture where live cells survive. It is only in such an environment that epidermal cells can move toward bridging the defect of the wound; therefore, the thicker the crust, the deeper the migration that is required. While scarring is associated with deep wounds and the loss of adnexal structures, improved cosmetic outcome has been observed following the use of occlusive dressings[2].

By reducing moisture transmission, moisture-retentive dressings optimize healing via several possible mechanisms. These include providing a moist environment (Fig. 145.1), increasing the availability of growth factors and matrix materials, and maintaining an electrical gradient within the wound, which also promotes healing.

HISTORY OF WOUND DRESSINGS

The use of wound dressings dates back to antiquity. For at least 4000 years, fabrics such as linen were employed, until woven absorbent cotton gauze was introduced in 1871. The Edwin Smith Surgical Papyrus, which is one of the earliest medical treatises (circa 1615 BCE), describes the use of linen strips and plaster to dress wounds, stating that closed wounds would heal more quickly than open wounds[2]. Ancient documents disclose how lint was used to pack and fill open wounds and how bandages were used to re-approximate wounds in order to facilitate healing. Linen strips were sometimes coated with grease or oil in order to prevent adherence to wounds or with honey to create a semi-occlusive and adherent dressing[3].

Until Lister connected the presence of pus with infection, pus had been viewed as beneficial ("laudable pus"). However, this association became linked so strongly that it was held that one is always indicative of the other, which is not always true. The association significantly interfered with the acceptance of occlusive dressings, despite better and faster healing, due to the fear of an increased number of bacteria under the dressing. Although the work of Pasteur, Koch, and Lister in the late 1800s on the cause of bacterial infections spurred the investigation of specific therapies for wound management, it was not until the mid-1900s that the understanding of wound healing changed.

Despite the teaching of the Smith Papyrus, it was believed that wounds healed faster if kept dry and uncovered. However, in 1948, Oscar Gilje described a "moist chamber effect" for wound healing[4]. Two years later, Schilling and colleagues studied common minor wounds with highly occlusive or semi-occlusive nylon films and found semi-occlusive dressings to be more effective for healing than open treatment. The finding that semi-occlusive dressings were more effective than the highly occlusive dressings is thought to have set back further study. In 1962, George Winter conducted the landmark study on moist wound healing, demonstrating a 30% greater benefit of occlusive dressings compared with air drying of wounds[1]. Many studies conducted since Winter's seminal work, including in the porcine model of wound healing, have supported the benefits of moist wound healing by occlusive dressings[5].

FUNCTIONS OF A WOUND DRESSING

The essential function of every dressing is to optimize the healing environment, but because the process of wound repair is dynamic (see Ch. 141), each stage may require a different dressing. While an ideal wound dressing would have many positive features (see Table 145.1), they should at the minimum protect the wound from trauma, bacterial invasion, or exposure to caustic substances; this is especially important during the acute inflammatory stage when promotion of granulation tissue formation and epithelialization is crucial. In addition, the dressing should be composed of a material that does not shed fibers or other material into the wound that could lead to foreign body reactions or irritant or allergic contact dermatitis[6]. The "ideal" dressing that meets all of these requirements for every wound type does not yet exist (Table 145.2). However, given the array of dressings available, it is possible to achieve one's goal.

Downloaded for Anonymous User (n/a) at Egyptian Knowledge Bank from ClinicalKey.com by Elsevier on March 10, 2024. For personal use only. No other uses without permission. Copyright ©2024. Elsevier Inc. All rights reserved.

TRADITIONAL WOUND DRESSINGS

Wound dressings can be categorized either by the dressing technique and how the dressing is utilized relative to the wound (see below) or by the composition and structure of the dressing[2]. Naturally occurring materials such as cotton, silk, linen, or cellulose-based substances have a long history of use and have been produced in various combinations for maximum clinical usefulness.

The basic cotton gauze bandages in use today are frequently composed of cotton plus cellulose acetate (added for increased absorbency) and are manufactured with or without various substances incorporated into the fabric. Gauze bandages are inexpensive and easy to use but have limited moisture-retentive capacity and may adhere to the wound; the moisture retentive properties can be enhanced by impregnation with hydrophobic coatings. White petrolatum and other ointments such as soft paraffin wax (e.g. Vaseline® gauze, Aquaphor® gauze, Adaptic™ dressing), with or without antimicrobial agents such as povidone-iodine (Betadine®), sulfadiazine, bismuth tribromophenate (Xeroform™ dressing), framycetin or chlorhexidine, are examples of impregnated substances. Balsam of Peru is found in the tulle gras dressing used predominantly in Western Europe. These medicated dressings are often composites of rayon, nylon, or gauze and are used for malodorous wounds such as chronic ulcers. Activated charcoal cloths (with or without antibacterial silver salt) are also used to control odor.

Because these impregnated dressings have less adherence to the wound, they are placed directly against the wound bed. In addition, they are less painful to remove and can be molded into the depression of deeper wounds for the purpose of filling dead space and providing absorption. The disadvantage of this type of dressing is the potential for maceration of the wound and the surrounding skin, should the dressing remain in place for an extended period of time. While traditional dressings such as gauze are relatively inexpensive and readily available, they require frequent replacement, which is time-consuming and can be costly due to the expense of nursing care[7].

Primary dressings are those that are in contact with the wound whereas *secondary* dressings cover the primary dressing and/or secure the primary dressing in place. Most conventional dressings are "layered" and are constructed as either "pressure" or "non-pressure" dressings. A layered dressing is usually created in three parts: (1) the contact or interface layer, which is usually a non-adherent, fluid-permeable material that makes direct contact with the wound; (2) the absorbent layer, usually a cotton pad, gauze or other such material, which is placed on top of the contact layer to "wick in" and retain wound exudate and help the dressing mold to the shape of the wound; and (3) the outer layer or wrap, often tape or other banding material for retention of the underlying layers. Each layer is placed in close approximation to the prior one, without gaps or air pockets, and should increase in size and degree of overlap, from wound bed to outermost layer.

A "pressure" dressing has more bulk added to the absorbent layer and is used to assist in hemostasis and to act as a bolster. Usually applied immediately after a surgical procedure such as debridement or graft placement (enhances graft–wound bed interaction), a pressure dressing is changed to a lighter dressing within 24 hours. In addition to limiting bleeding, the pressure dressing also reduces local edema. However, it is important to be aware of the amount of pressure exerted upon the wound bed so as not to create localized ischemia, potentially resulting in tissue necrosis[8].

FIRST AND SECOND INTENTION HEALING

Typically, primary closure is employed for postsurgical wound defects that are clean and free of debris. Aseptically placed sutures provide hemostasis, reduce the possibility of wound infection, and may improve

SELECTION OF APPROPRIATE DRESSINGS	
Wound factor	**Dressing**
Exudate	
• Provides moisture	Hydrogel
• Maintains moisture	Film, hydrocolloid
• Absorbs moisture	Foam, alginate, gelling fibers, superabsorbent
Pain	
• Reduces pain	Hydrogel, soft silicone, contact layers
Bleeding	
• Contains hemostatic agents	Alginates
Superficial infection	
• Reduces number of microorganisms	Impregnated with silver, chlorhexidine, polyhexamethylene biguanide, iodine, honey, copper oxide, dialkylcarbamoyl chloride, or methylene blue plus gentian violet as antiseptics

Table 145.1 Selection of appropriate dressings. Availability and cost are two additional factors that are not wound-related.

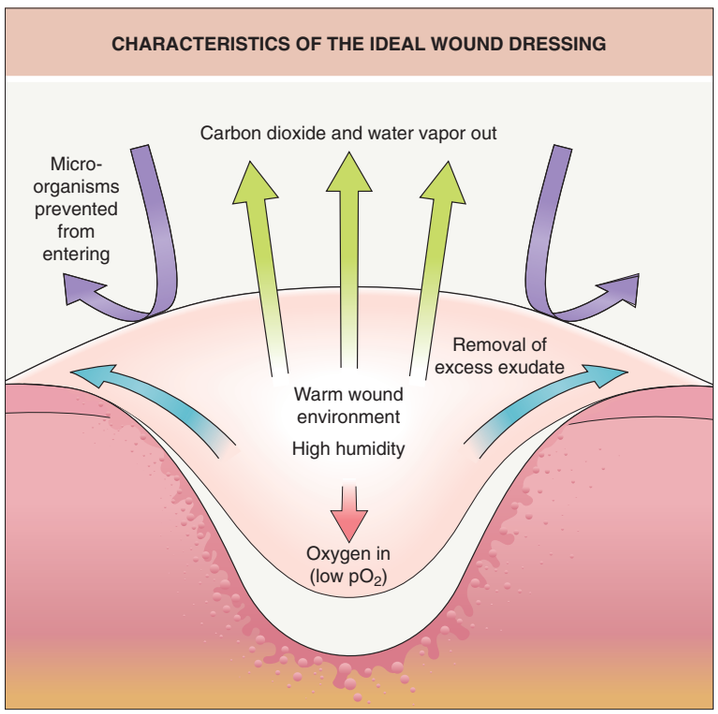

Fig. 145.1 Characteristics of the ideal wound dressing. *Courtesy Gregg M. Menaker, MD.*

CHARACTERISTICS OF AN IDEAL DRESSING – COMPARISON OF MOISTURE-RETENTIVE DRESSINGS					
	Comfort	**Absorbency**	**Pain relief**	**Easy to re-apply**	**Debridement**
Films	+		+		+
Foams	+	++	+	+	
Hydrogels	++	+	++	+	++
Alginates	++	+++		+	+
Hydrocolloids	+	++	+	+	+
Superabsorbents	+	+++		+	

Table 145.2 Characteristics of an ideal dressing – comparison of moisture-retentive dressings[e1].

Downloaded for Anonymous User (n/a) at Egyptian Knowledge Bank from ClinicalKey.com by Elsevier on March 10, 2024. For personal use only. No other uses without permission. Copyright ©2024. Elsevier Inc. All rights reserved.

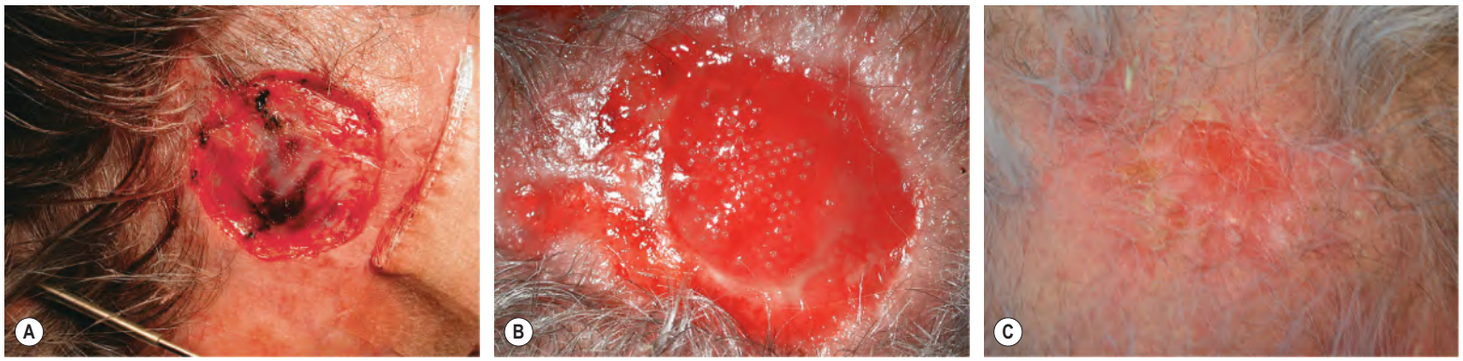

Fig. 145.2 Second intention healing. A Surgical wound immediately following Mohs micrographic surgery; a semi-occlusive dressing will be applied. **B** Three weeks following surgery. Note the abundance of pink–red granulation tissue. **C** Fully re-epithelialized wound six weeks following surgery. *Courtesy Gregg M. Menaker, MD.*

the ultimate cosmetic result. After suture removal, the use of external splinting tape (e.g. Steri-Strips™) or tension-relieving dressings (e.g. embrace®) supports the tissues, enabling favorable collagen remodeling that may limit scar formation and hypertrophy. Use of an antimicrobial ointment under the dressing does not reduce the rate of infections but does increase the risk of contact dermatitis, while the use of any ointment did not reduce complications[9,10].

Second intention healing is often employed following cutaneous surgical techniques such as tangential biopsy, curettage, cryosurgery, laser surgery, and excision in concave sites (Fig. 145.2). In such cases, moisture in the wound bed is the key to optimal healing. A semi-occlusive dressing is the treatment of choice, with the topical application of ointment directly on the wound. Monitoring the wound for signs of infection and preventing the wound bed from drying until re-epithelialization has occurred are usually sufficient measures for the management of this type of surgical wound[11].

ROLE OF DEBRIDEMENT

Debridement is the removal of necrotic, contaminated, or foreign material from a wound or from areas adjacent to the wound. Although data from controlled trials are limited, it is considered a key component of wound management due to its purported ability to induce acute healing and reduce microorganisms[12]. Five types of debridement exist: surgical, mechanical, autolytic, enzymatic, and biologic. Although *surgical* debridement is often the fastest and most direct way of removing unhealthy tissue, it may not be the method of choice for all patients. Factors such as the frequent need for analgesics, possible bleeding, the extent of non-viable tissue, patient preferences, and the practitioner's level of expertise need to be considered. An example of *mechanical* debridement is the wet-to-dry dressing that is employed for wounds with significant necrotic tissue, but it does not distinguish between viable and non-viable tissue.

In *autolytic* debridement, occlusive dressings provide a moist wound environment which promotes the lytic activity of enzymes present in accumulated wound fluid. This assists in the clearance of residual debris during early wound healing. *Enzymatic* (chemical) debridement involves the topical application of an enzymatic agent and this can be used to supplement autolytic debridement. Currently, one agent is FDA-approved: collagenase (Santyl®) ointment. It assists in the removal of devitalized tissue and aids in granulation tissue formation and re-epithelialization.

Biologic debridement employs fly larvae (maggots) and has been used for centuries to debride chronic ulcers. Nowadays, the most commonly used maggots are those of the green bottle fly, *Lucilia sericata*. Maggots digest necrotic tissue via collagenases and trypsin-like enzymes, thereby exposing healthy tissue. They also have antimicrobial effects, including secretion of antibacterial compounds (e.g. phenylacetic acid, phenylacetaldehyde) in addition to ingestion and subsequent killing of Gram-positive bacteria (including MRSA) and, to a lesser extent, Gram-negative bacteria. In a clinical trial of 267 patients with leg ulcers, larval therapy led to faster debridement than hydrogel therapy, but larval therapy has not been shown to improve healing rates or decrease bacterial load[13,14].

WOUND CLEANSERS

The removal of loose debris from the wound surface is termed *wound cleansing* and is a component of local wound care[15]. Optimal wound cleansers should have low cytotoxicity and they include water, isotonic normal saline (0.9% sodium chloride), and in some cases, dilute acetic acid or other mild acid solutions. Isotonic normal saline is a good cleanser for the majority of wounds and a Cochrane collaboration review found clean tap water as a suitable alternative[16].

Wound cleansing can be performed via several methods: compresses (gauze squeezed so no excess fluid), soaking (saturated gauze), cleansing sprays, and high-pressure irrigation. Irrigation can cause trauma to the wound bed and is not recommended for deep wounds unless one makes sure no cleansing fluid is retained within a "pocket" in the wound.

TOPICAL ANTIMICROBIALS AND DRESSINGS THAT CONTAIN ANTIMICROBIAL AGENTS

The presence of bacteria in wounds may delay acute wound healing, depending upon the quantity, species, and variants of bacteria as well as their organization within the wound (e.g. biofilms). They may also contribute to delayed healing of chronic wounds, but because resident bacteria are often held in check by host resistance, most chronic wounds heal with bacteria present. That said, bacteria do compete with adjacent cells for oxygen and nutrients and they can also produce toxins that delay healing. Bacteria within wounds can also form biofilms which are complex adherent accretions that are difficult for antibiotics to penetrate. Clinically differentiating a wound in bacterial balance from a wound where bacteria are delaying healing remains a challenge.

While a clean wound created with good aseptic technique (e.g. sutured surgical excision) does not require topical antimicrobials[9,10], they may be needed for some acute and chronic wounds with critical colonization. Topical antimicrobial agents include antiseptics and antibiotics. Antiseptics non-selectively destroy or inhibit the growth of microorganisms, whereas antibiotics are only effective against specific bacteria[17]. Due to the emergence of bacterial resistance and the risk of development of allergic contact dermatitis, topical *antibiotics* are typically reserved for superficial cutaneous infections such as impetigo. Mupirocin, retapamulin, ozenoxacin and fusidic acid are indicated for the treatment of cutaneous infections due to *Staphylococcus aureus* or *Streptococcus pyogenes*[18,19]. Silver sulfadiazine has broader antimicrobial coverage, but a pseudo-eschar can form and may delay healing[19,20]. Triple antibiotic cream or ointment formulations available over the counter may contain combinations of polymyxin, gramicidin, bacitracin, and/or neomycin; however, the latter two are amongst the most common allergens in North America (see Ch. 14).

Because *antiseptics* often affect cellular metabolism (including cell wall formation), they are less often associated with the emergence of resistant organisms. The antimicrobial activity and cellular toxicities of various antiseptics are listed in Table 145.3[17,21]. ***Silver*** has been used since ancient times for treating wound infections due to its antimicrobial activity. When in contact with wound fluid, silver metallic salt (Ag^0) becomes ionized (Ag^+) and highly active against bacteria.

Downloaded for Anonymous User (n/a) at Egyptian Knowledge Bank from ClinicalKey.com by Elsevier on March 10, 2024. For personal use only. No other uses without permission. Copyright ©2024. Elsevier Inc. All rights reserved.

DRESSINGS THAT CONTAIN ANTISEPTICS				
Antimicrobial agent	**Examples of dressings**	**Coverage spectrum**	**Advantages**	**Disadvantages**
Silver	Acticoat® Flex 7 Silver, Actisorb® Silver 220, Algicell® Ag (alginate), Aquacel® Ag, Contreet® Biatain Ag Foam, ColActive® Plus Ag, Mepilex® Ag, Opticell™ AG+ (gelling fiber), PolyMem®/ PolyMem MAX Silver, SilvaSorb® (hydrogel), Silvercel® (alginate), Silverlon®, Tegaderm™ Ag (alginate), UrgoTul® Ag/Silver, UrgoTul® SSD	Broad-spectrum antibacterial, including MRSA and VRE	• Release antibacterial levels of silver for 3–7 days • Appear to decrease the levels of matrix metalloproteinases that are upregulated in non-healing, chronic wounds • Microbial resistance is rare • Variety of products available for different wound situations • Infrequent application required	• Silver may stain tissues (localized argyria) • Relatively expensive • Slows acute wound healing
Chlorhexidine or polyhexamethylene biguanide (PHMB), a chlorhexidine derivative	Bactigras™ (chlorhexidine), GemCore360° (PHMB), Kendall™ AMD foam (PHMB), Kerlix™ AMD gauze (PHMB), PuraPly® AM (PHMB)	Broad-spectrum antibacterial and antifungal	• Low tissue toxicity • Different forms available, including foam, ribbons, and gauze • Comforting so recommended for painful wounds	• May cause stinging and ICD • Cytotoxicity – cornea, inner ear (in the setting of tympanic membrane rupture), and cartilage • Systemic and local hypersensitivity reactions
Povidone-iodine* Cadexomer-iodine polymer* Other iodophors	Inadine®, Betadine® cream applied to gauze, Iodoflex™, Iodosorb® (gel), Ioplex®	Broad-spectrum antimicrobial – bacteria, fungi, viruses	• Less irritating to skin than iodine alone • Cadexomer-iodine polymer does not inhibit wound healing	• May cause stinging • ICD, ACD • Povidone-iodine can inhibit wound healing
Honey	Activon Tulle, First Honey® Manuka, MEDIHONEY® Calcium (alginate), MEDIHONEY® gel	Broad-spectrum antimicrobial – bacteria, fungi, viruses	• Low tissue toxicity • Autolytic debridement	• May cause maceration • ACD to propolis
Methylene blue and gentian violet	Hydrofera Blue® Classic, READY, READY-Transfer	Broad-spectrum antibacterial, including MRSA and VRE, and anti-candidal	• Less irritating • Good absorptive capacity for cavity wounds	• Bacteriostatic
Methylene blue, gentian violet, and silver	RTD™ (Retro-Tech Dressing)	Broad-spectrum antibacterial, including MRSA and VRE, and anti-candidal	• See silver above • See methylene blue and gentian violet above	• See silver above • See methylene blue and gentian violet above
Hypertonic saline	Mesalt®	Broad-spectrum antibacterial	• Less irritating to skin	
Copper oxide	MedCu®	Broad spectrum antibacterial, antifungal and antiviral	• Can be incorporated into fabric, including masks	
Dialkylcarbamoyl chloride (DACC)	Cutimed® Sorbact® (contact layer)	Broad spectrum, anti-candidal	• Reduces inflammation by trapping bacteria rather than killing bacteria • Variety of dressing types available	• Bacteriostatic
*Not to be used in young children, pregnant or lactating women, or individuals with a known iodine sensitivity; to be used cautiously in patients with thyroid disorders.				

Table 145.3 Dressings that contain antiseptics. ACD, allergic contact dermatitis; ICD, irritant contact dermatitis; MRSA, methicillin-resistant *Staphylococcus aureus*; VRE, vancomycin-resistant enterococci. From refs 18, 19, 23–25, 27, 31, 33, 36, e2, e3.

The bactericidal action of ionized silver can be explained by the binding of silver ions to tissue proteins or by reactions with chloride anions, which then bind to bacterial DNA and RNA and alter bacterial cell walls and nuclear membranes[22]. Silver also has anti-inflammatory effects and may have angiogenic properties. In addition, silver ions decrease the levels of matrix metalloproteinases (MMPs) that are often upregulated in non-healing wounds. Despite these effects, a recent Cochrane review found no significantly higher healing rates with silver dressings, suggesting that short-term use is optimal[23,24]. Newer dressings, in which high-density polyethylene mesh is impregnated with nanocrystalline silver (Fig. 145.3)[25], can release antibacterial levels of silver for 3–7 days[26].

Chlorhexidine gluconate is a biguanide antiseptic with a wide range of antimicrobial activity against Gram-positive and Gram-negative bacteria, yeasts, and molds, but it is recommended for intact skin not open wounds as it works by disturbing the cytoplasmic membrane[27]. Despite data that it can inhibit re-epithelialization, chlorhexidine-containing dressings have been used in wounds and burns with reported benefit[28]. Because there can be associated cytotoxicity, especially to the cornea, inner ear (in the setting of tympanic membrane rupture), and cartilage, exposure to these structures should be avoided[29]. Systemic and local hypersensitivity reactions have also been observed. A chlorhexidine derivative, polyhexamethylene biguanide (PHMB), appears to be safer and has been added to several wound dressings including gauze, ribbons, foam, and hydrogels.



Fig. 145.3 A variety of silver dressings. Clockwise from 2 o'clock, Silvercel®, PolyMem® MAX® Silver, Acticoat® Flex 7 Silver, ColActive® Plus Ag, and Restore® Silver.

Downloaded for Anonymous User (n/a) at Egyptian Knowledge Bank from ClinicalKey.com by Elsevier on March 10, 2024. For personal use only. No other uses without permission. Copyright ©2024. Elsevier Inc. All rights reserved.

Iodine is a broad-spectrum antiseptic that is available in different formulations[30]. However, povidone-iodine, a commonly used antiseptic, can inhibit wound healing. In contrast, newer formulations such as cadexomer-iodine polymer, which slowly releases iodine from dextran beads, do not slow healing and have not been found to have toxic effects on keratinocytes. The starch lattice in the cadexomer-iodine polymer is highly absorptive (1 gram absorbs up to 7 ml of fluid) and as the fluid is absorbed, the iodine is slowly released[31]. The iodine confers antimicrobial activity for several days, but is in a low enough concentration that cytotoxic effects are avoided. The frequency of dressing changes is determined by the rate of iodine release, which is largely dependent on wound exudate[32].

Studies in patients with venous leg ulcers have shown a significant decrease in ulcer size when cadexomer-iodine was compared to hydrocolloid and paraffin gauze dressings[33]. When compared to other treatments for diabetic foot ulcers, cadexomer-iodine was associated with a cost benefit[34]. Because iodine can be absorbed systemically, caution is required when using these dressings in patients with a history of thyroid disease. They should not be used in young children, pregnant or lactating women, or patients with known iodine sensitivity.

While first used centuries ago, ***honey*** has experienced a resurgence due to recognition of its antimicrobial properties. The latter is related to honey's high osmolality, which minimizes the availability of water to bacteria[35]. Manuka honey, a commonly used type of honey, also contains flavonoids and aromatic acids that have antimicrobial properties. In addition, honey exhibits an anti-odor effect by decreasing the wound pH; release of hydrogen peroxide and glucuronic acid stimulates macrophages/monocytes, promotes inflammatory cytokine production, and provides analgesic and antibacterial effects[36]. A Cochrane review found that topical treatment of superficial and partial-thickness burns with honey may improve healing when compared to some conventional dressings[37,38].

Methylene blue and ***gentian violet***, two organic dyes, have been combined in a polyvinyl alcohol sponge to produce an antimicrobial dressing (Hydrofera Blue® Classic, READY, READY-Transfer)[39]. These dyes are not released from the dressing, thus avoiding previously reported tissue toxicities. The dressing has broad-spectrum activity against Gram-positive bacteria, Gram-negative bacteria, and *Candida* spp. These two organic dyes have also been combined with silver in a polymer matrix-containing foam dressing (RTD™).

Copper oxide has demonstrated broad-spectrum bactericidal as well as pro-angiogenic effects and therefore has been incorporated into a dressing[40]. In wounded diabetic mice treated with copper oxide dressings, enhanced angiogenesis post-wounding was observed along with upregulation of proangiogenic factors, including placental growth factor, hypoxia-inducible factor-1 alpha, and vascular endothelial growth factor[41].

Dialkylcarbamoyl chloride (DACC) is a highly hydrophobic fatty acid derivative that can irreversibly bind bacteria via hydrophobic interactions. DACC has been incorporated into a variety of dressings and in a controlled clinical trial reduced the short-term incidence of postsurgical skin infections compared to a standard dressing[42].

MOISTURE-RETENTIVE DRESSINGS

Moisture-retentive dressings, traditionally called passive dressings, are distinct from active dressings, with the former commonly divided into six major groups: films, foams, hydrogels, alginates/gelling fibers, hydrocolloids, and the most recent addition, superabsorbent dressings (Fig. 145.4; Table 145.4). In choosing the most appropriate dressing for a particular wound, it is important to strike a moisture balance, i.e. not too dry and not too wet.

Films

Polymer films are thin, self-adhesive, transparent sheets of polyurethane or other synthetic semipermeable material (Fig. 145.5). These dressings are gas permeable, allowing for the exchange of oxygen, carbon dioxide and water vapor, but impermeable to larger molecule efflux, due to their pore size. Therefore, bacteria, proteins and wound fluid are prevented from moving across the dressing. Its permeability to water vapor allows for the release of insensible water and sweat from the skin. This provides the potential advantage of preventing maceration of the wound and surrounding skin. The semi-occlusive nature of this dressing allows for passage of oxygen to the wound, which had been considered to be an important feature when these dressings were initially introduced. Since then, evidence has indicated that low pO_2 levels (similar to those that actually exist under the dressings) facilitate healing.

Advantages/disadvantages

The advantages of this type of dressing include translucency, thereby allowing direct visualization of the wound without removal of the dressing; permeability to water vapor; and tendency to reduce postoperative pain. They enhance re-epithelialization of graft donor sites, with a reported increase in healing rates of 25%–45%[43]. One disadvantage of film dressings is that they are difficult to place properly, requiring uniform tension on the film to prevent wrinkling and its adherence to itself (similar to what is experienced with Saran™ Plastic Wrap). As the film usually only adheres to intact skin, a 1–2 cm application margin is recommended. In addition, due to shearing forces, it is best to avoid using films on thin or fragile skin.

Films may adhere to the wound as drying progresses, thereby risking disruption or stripping of the newly formed epithelium that is not yet tightly bound to the underlying dermal layer. It is also possible to traumatize newly grafted skin tissue during dressing changes. For these reasons, it is advisable to allow the film dressing to remain in place until it spontaneously falls off, which occurs after 1–2 weeks[44]. Any wrinkling of the film during placement can create a conduit for bacterial penetration and leakage of wound exudate. It is therefore recommended that for exudative wounds the film have a complete 2–3 cm adhesion margin to prevent this leakage.

Another disadvantage of film dressings is that they are non-absorbent; therefore, wound fluid can accumulate under the dressing layer, especially with highly exudative wounds. This is often the case during the first 7–10 days after the creation of a wound, with the adherent properties of film dressings making frequent changing undesirable.

Foams

Polymer foams are semi-occlusive, bilaminate, and polyurethane- or silicone-based dressings. They consist of a hydrophilic foam with a hydrophobic backing, which can prevent leakage, provide a barrier against bacterial penetration, and provide the moist environment afforded by films, but with the addition of some absorbency (Fig. 145.6). The inner layer is composed of an absorbent, gas-permeable polyurethane foam mesh, which lies adjacent to the wound. The outer layer is a semipermeable, non-absorbent membrane composed of polyurethane, polyester, silicone or Gore-Tex®, surrounded by a polyoxyethylene glycol foam. This layer protects against outside bacterial contamination to some extent and against the drying out of the underlying layers.

Foam dressings are typically non-adherent, thereby requiring secondary dressing layers to ensure secure placement with a good seal. The quality of the seal is important to prevent leakage, desiccation, and problems with adherence. There are, however, some foams available with an adhesive surface and/or border, usually surrounding a central absorptive core. Ideally, once a foam dressing has absorbed some amount of exudate, it should be able to retain that fluid, even if exposed to pressure. Some brands are described as having such a quality.

Advantages/disadvantages

Although absorbent, there is usually a limit to the amount of wound exudate this type of dressing can absorb. Therefore, it should be changed every 1–3 days. The permeability of foams to both gas and water vapor makes them suitable for mild to moderately exudative wounds, although some brands may accommodate highly exudative wounds.

Silicone-based rubber foams, known as silastic foams, are composed of a silicone mixture to which a stannous octoate catalyst has been added. This type molds and contours to the shape of the wound and therefore can be used for packing cavities or deep ulcers such as pilonidal sinuses. The additional advantages are absorbency, non-adherence, increased comfort for the patient, a tendency to be less expensive, and dressing changes that do not generally require skilled nursing care[45].

The disadvantages of foam dressings are the inability to use them with dry wounds, their opacity, which prevents visual monitoring of the wound, and the need for frequent changing, perhaps as often as every day. Infrequent changing could risk incorporation of the dressing

Downloaded for Anonymous User (n/a) at Egyptian Knowledge Bank from ClinicalKey.com by Elsevier on March 10, 2024. For personal use only. No other uses without permission. Copyright ©2024. Elsevier Inc. All rights reserved.

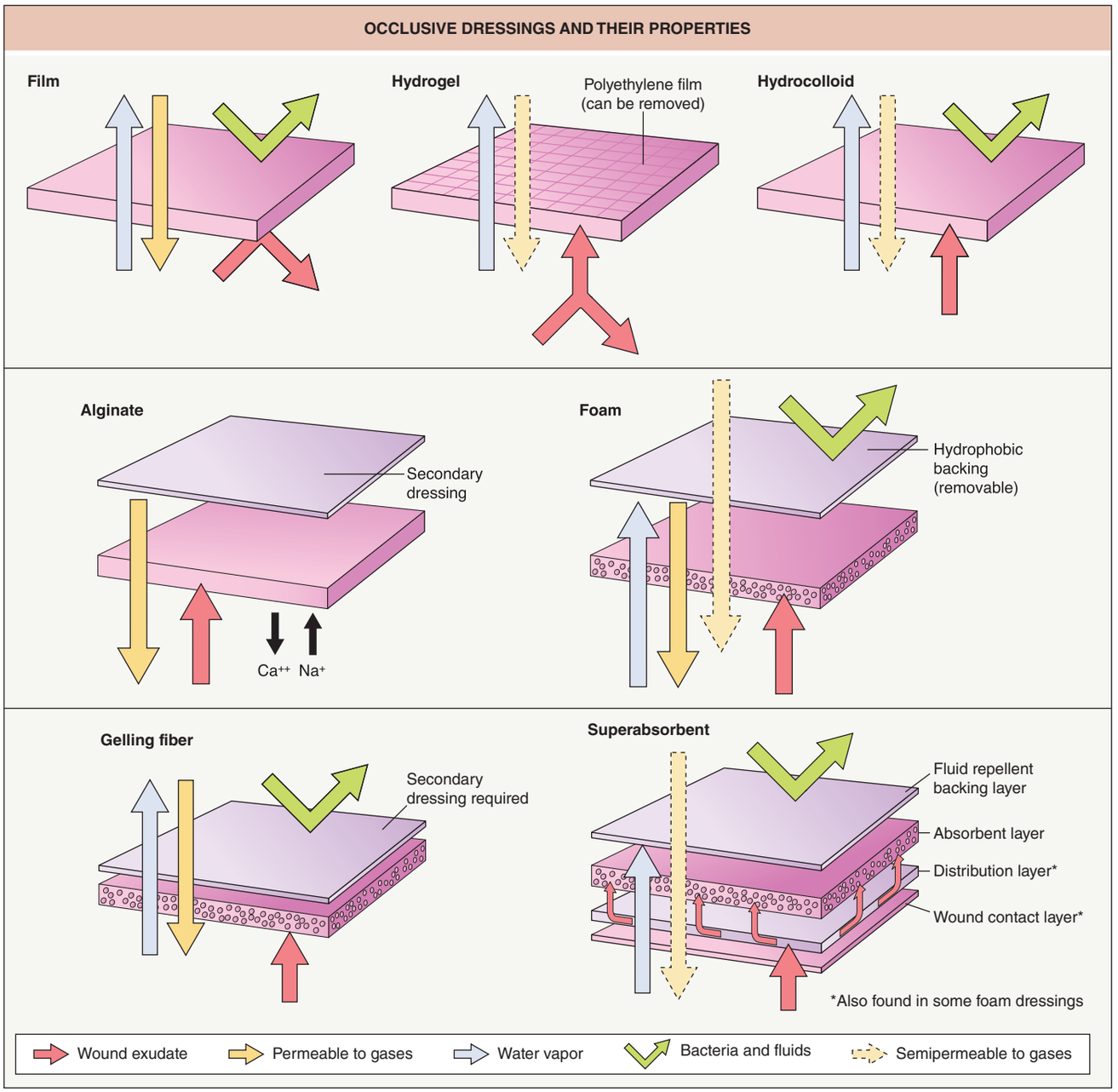

Fig. 145.4 Occlusive dressings and their properties. The six major dressings are polymer films, polymer foams, hydrogels, alginates/gelling fibers, hydrocolloids, and superabsorbents. *Courtesy Gregg M. Menaker, MD.*

material into the wound itself. There is also the possibility of an undesirable drying effect of the wound if drainage is insufficient to maintain a moist environment.

Hydrogels

As their name implies, hydrogels are composed primarily of water – up to 96% of the content. This dressing type consists of a cross-linked hydrophilic polymer network composed of polyvinyl alcohol, polyacrylamide, polyethylene oxide or polyvinyl pyrrolidone; it is produced as sheets, amorphous gels (pre-mixed or dry), or as impregnated dressings (Fig. 145.7). Hydrogels are semitransparent (allowing visual inspection of the wound), have a high absorptive capacity (between 100% and 200% of their volume), and are able to maintain a moist wound environment. The absorptive action is delayed in its onset and increases slowly as it provides for continuous, long-term absorption. Hydrogels are described as semi-adherent or completely non-adherent, depending upon the type, and therefore require a secondary dressing to hold them in place[46]. The latter is necessary, as hydrogels provide a poor bacterial barrier and selectively permit Gram-negative organisms to proliferate[47].

In general, the *sheet form* of a hydrogel dressing is constructed by sandwiching the hydrophilic polymer between two removable thin sheets of polyethylene film, with some types containing a supportive inner gel mesh. For application to the wound, the film on the contact side is removed, leaving the outer film in place. With this mode of application, the dressing is semipermeable to gases (including oxygen) and water vapor. If the outer film is also removed, then the dressing becomes permeable to fluid as well; as a result, exudate can pass to a secondary gauze dressing. The polymer sheets can be removed easily without trauma to the wound bed.

The *amorphous type* of hydrogel is composed of a cornstarch-derived, polymerized compound that forms a gel upon hydration at the time of its use. It is available commercially in a powdered or pre-mixed form, is applied wet to the wound defect, requires a secondary outer dressing, and requires water application to the surface for removal.

Advantages/disadvantages

One significant advantage of hydrogel dressings is a reduction in postoperative pain and inflammation. Another is that hydrogels have been shown to accelerate the rate of wound healing when compared to gauze

Downloaded for Anonymous User (n/a) at Egyptian Knowledge Bank from ClinicalKey.com by Elsevier on March 10, 2024. For personal use only. No other uses without permission. Copyright ©2024. Elsevier Inc. All rights reserved.

MOISTURE-RETENTIVE DRESSINGS						
Dressing type	**Examples**	**Composition**	**Permeability**	**Indicated uses**	**Advantages**	**Disadvantages**
Films	Bioclusive™, Blisterfilm™ Transparent Film Dressing (TFD), Carrafilm™, Derma View II, Mefilm®, Mepore® Film, Opsite™, Polyskin® II, Tegaderm™ Film, Transeal® TFD	Thin polyurethane sheet	Semipermeable	• Intravenous sites • Skin tears • Split-thickness graft donor sites • Laser resurfacing • Mohs surgery defects • Holding pinch grafts in place for venous leg ulcers	• Translucent • Permeable to water vapour • Pain reduction • Creates bacterial barrier	• Difficult to position properly • May adhere to wound as it dries • Possible exudate accumulation • Non-absorbent
Foam	*Adherent and non-adherent*: Allevyn™, Biatain™, Biopatch®, CuraFoam™, Flexzan®, Hydrasorb®, Lyofoam®, Mepilex®, Optifoam®, PolyMem®, Reston™, Sof-Foam™	Bilaminate polyurethane or silicone	Semipermeable	• Chronic wounds • Surgical excisions • Dermabrasion • Burns • Mohs surgery defects • Laser resurfacing	• Absorbent • Permeable to water vapour • Conforms to wound shape • Thermally insulates • Comfortable	• Opaque • Cannot be used on dry wounds • Possible undesirable drying effect on inadequately exudative wounds
Hydrogels	*Hydrogel sheets*: ActiFormCool®, AquaDerm™, Aquaflo®, AquaSite®, CarraDres™, CarraSorb™ M Freeze Dried Gel, Flexigel®, Vigilon® *Amorphous gels*: Biolex® Wound Gel, Carrasyn® Hydrogel, Hydrogel GRX®, Hypergel®, Intrasite™ Gel, Normlgel®, Tegagel™ Hydrogel Wound Filler *Impregnated dressings*: AquaSite™ gauze, Curafil® gauze, Curagel®, DermaGauze™, Tegagel™ Hydrogel Wound Filler with gauze	Hydrophilic polymer sheets, gel, and impregnated dressings	Semipermeable with outer membrane in place	• Dry wounds • Dermabrasion • Laser resurfacing • Superficial thermal burns • Chemical peels • Graft donor sites • Partial thickness wounds	• Semitransparent • Donates fluid to necrotic tissue • Soothing, cushioning and cooling effect, reduction of postoperative pain • Available in sheets, powdered or pre-mixed amorphous gels • Low trauma at dressing changes • Reportedly helpful for pruritus	• No spontaneous sucking ability • Absorption is slow • Requires secondary dressing • Caution in infected wounds
Alginates	Algicate Ag, AlgiCell®/ Algicell® Ag, AlgiSite™ M, Algosteril®, CarraGinate™, CarraSorb™ H, Fibracol® Plus (collagen [90%]–alginate [10%]), Kalginate™, Kaltostat®, Maxorb®, MedVance™, Melgisorb® Plus/Melgisorb® Ag, Sorbsan®/Sorbsan® Silver	Seaweed-based complex polysaccharide	Semipermeable	• Chronic highly exudative wounds • Full-thickness burns • Surgical wounds • Split-thickness graft donor sites • Mohs surgery defects	• Highly absorbent with spontaneous sucking ability • Hemostatic properties • Non-adherent • Conforms to wound shape • Soluble for low trauma dressing changes with normal saline	• Requires a secondary dressing to prevent desiccation • Gel has unpleasant appearance and odor • Mild burning sometimes reported upon application
Gelling fibers	Aquacel®, Exufiber®, Opticell®	Polyvinyl alcohol, sodium carboxymethyl cellulose, chitosan-based polysaccharide polymers	Semipermeable	• Moderate to highly exudative wounds	• Handles heavy exudate • Locks in exudate to reduce maceration • When removed, does not fall apart	• If no exudate, can adhere to wound • Requires a secondary dressing
Hydrocolloids	Allevyn™, Comfeel®, DuoDERM®,DynaDerm®, Exuderm®, Hydrocol® II, MedVance™, Nu-Derm®, Primacol®, RepliCare™, Restore®, Tegaderm™ Hydrocolloid, Tegasorb™	Starch or plastic woven polymer, dextran, polyethylene glycol, water	Semipermeable	• Chronic ulcers • Burns • Traumatic wounds • Surgical wounds • Dermabrasion • Inflammatory disorders (e.g. lichen simplex chronicus)	• Capillary action facilitates debris removal • Conforms to wound shape • Directly adheres to wound site and is easy to use • Increased patient comfort • Thermal insulation	• Risk of maceration of surrounding skin • Possible wound trauma with dressing change • Gel has unpleasant appearance and odor • Opaque • Caution in infected wounds • Collected exudate often confused with wound infection • Excessive granulation tissue (prolonged use)

Table 145.4 Moisture-retentive dressings[40,49].

Continued

Downloaded for Anonymous User (n/a) at Egyptian Knowledge Bank from ClinicalKey.com by Elsevier on March 10, 2024. For personal use only. No other uses without permission. Copyright ©2024. Elsevier Inc. All rights reserved.

MOISTURE-RETENTIVE DRESSINGS						
Dressing type	**Examples**	**Composition**	**Permeability**	**Indicated uses**	**Advantages**	**Disadvantages**
Superabsorbent	Flivasorb®, KerraMax®, Mextra®, OptiLock®, Sorbion®	Polyacrylic acid polymers	Semipermeable	• Moderate to highly exudative wounds	• Handles heavy exudate • Locks in exudate to reduce maceration • When removed, does not fall apart	• Caution when applied under compression • May adhere to wound if exudate dries
Contact layers	Adaptic Touch™, Cutimed Sorbact WCL, Mepitel® One, UrgoTul®	Flexible polyester mesh	Permeable (non-occlusive)	• Contact layer for wounds	• Non-adherent • Less pain with dressing change	• Not recommended for stage 1 pressure ulcers, third-degree burns or wounds with eschar
Silicone dressings	Mepilex® (foam), Mepitel® (film), Mepilex® Transfer (foam), Mepitel® Border (foam)	Silicone-based	Semipermeable Suitable as primary or secondary dressings	• Bullous disorders including epidermolysis bullosa • Fragile skin	• Absorbent • Non-adherent	• Opaque

Table 145.4 Moisture-retentive dressings[40,49].

Fig. 145.5 A transparent film dressing is used to occlude a dry wound. This example is Tegaderm™.

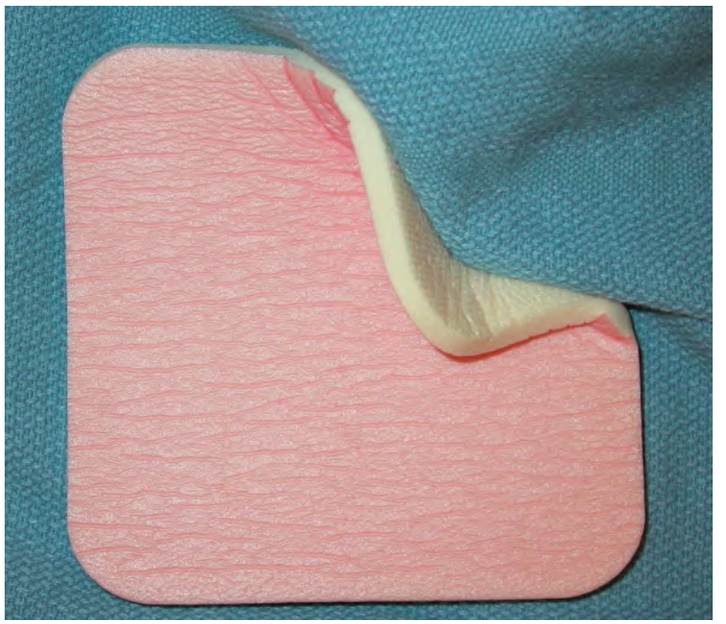

Fig. 145.6 Polymer foam dressing. It consists of hydrophilic foam with a hydrophobic backing (pink).

dressings and non-adherent dressings such as Telfa™. For example, the rate of re-epithelialization of split-thickness porcine wounds was 25%–45% faster with hydrogels, and 100% of the hydrogel-treated wounds healed by postoperative day 4 compared with 32% of open-air (control) wounds[48]. Hydrogels have also been credited with faster healing rates in studies of dermabrasion and hair transplant donor and recipient sites, when compared to standard non-adherent dressings[49].

Hydrogels are not recommended for infected wounds. In addition, the semi- or non-adherent nature of hydrogels often results in more frequent dressing changes than is needed with other occlusive dressings.

Alginates

Highly absorbent alginate dressings are composed of a natural, complex polysaccharide derived from various types of algae or kelp (seaweed). An extraction process produces a sodium salt form of alginic acid and, during a second step, sodium ions are exchanged for calcium, zinc, and magnesium. The end result is an alginate fiber; non-woven mats or twists of this fiber are then made into a dressing (Fig. 145.8). Upon application of the dressing, a reverse ion exchange occurs between the calcium within the alginate fibers and the sodium from blood or the wound exudate. This results in the formation of a soluble sodium alginate gel that fills and completely covers the wound in a non-adherent manner, providing a moist wound healing environment. The extent and rate of gel formation depends on the amount of wound exudate. Alginate dressing materials also have hemostatic properties, believed to be the result of the release of free calcium by the fibers during the ion exchange. This release of calcium augments the clotting cascade, producing the hemostatic advantage.

Because alginate gel dressings are highly absorbent, they can remain in place at the wound site for several days at a time, thereby minimizing dressing changes. To secure an alginate dressing, a secondary dressing is required. A dressing change is indicated when the dressing has been in place for several days or when exudate soaks through to the secondary dressing[50]. Removal of the dressing in a dried state can re-injure the wound.

Advantages/disadvantages

Alginate dressings are soluble and can be removed by saline irrigation, permitting less painful dressing changes. They have been shown to encourage wound healing and are metabolized by the body, should residual material remain at the wound. Despite concerns about the potential toxicity of alginates, they have been used for over 50 years without any commonly reported complications. However, removal of the secondary outer dressing is necessary to visually inspect the wound and to monitor for desiccation.

Downloaded for Anonymous User (n/a) at Egyptian Knowledge Bank from ClinicalKey.com by Elsevier on March 10, 2024. For personal use only. No other uses without permission. Copyright ©2024. Elsevier Inc. All rights reserved.



Fig. 145.7 Hydrogels. A Hydrogel sheet. **B** Premixed amorphous hydrogel.

Fig. 145.8 Collagen–alginate complex dressing. Alginate dressings have hemostatic effects and can be used post-debridement.

Gelling Fibers (Hydrofibers)

Highly absorptive hydrofibers are another category of dressings with similarities to alginates. They are composed of carboxymethyl cellulose fibers that interact with wound fluid, turn into a gel, and aid in autolytic debridement[51]. Gelling fibers are up to three times more absorbent than alginates. An additional advantage over alginates is their vertical uptake of wound fluid, thereby decreasing the risk of peri-wound maceration.

Hydrocolloids

Colloid is a Greek term for a two-phase system comprised of a uniform dispersion of one phase of matter (unfilterable small particles) into another phase of matter or matrix. Mutually attractive charges exist between the particles, which contributes to the diffusible properties of colloids. Colloids are characterized by the strength of attraction of the particles to the continuous medium and to the proportion of water within that medium. This property accounts for the absorptive and expansive capacity of colloid gels, which function as a semipermeable membrane. Gel swelling occurs because the particle concentration of the gel is usually higher than that of the surrounding medium, thereby drawing water from the surroundings into the gel.

Fig. 145.9 Hydrocolloid dressing placed over a healing wound on the ankle. This example is DuoDERM®.

Hydrocolloid dressings were first employed as ostomy products and are now available in multiple forms. The most commonly used hydrocolloid dressings (e.g. DuoDERM®) are available as sheets with an inner adhesive layer consisting of a hydrophilic colloid base that is a mixture of pectin, karaya, guar or carboxymethyl cellulose plus an adhesive containing polyisobutylene, styrene isoprene, or ethylene vinyl acetate (Fig. 145.9). The outer layer is composed of a thin semipermeable material such as polyurethane. A gel is formed in the presence of wound exudate, and as a unit, the dressing is semipermeable to water vapor and gases[52].

Another type of hydrocolloid dressing is a synthetic, non-adherent, high-density plastic woven polymer (e.g. N-Terface®). Fluid is able to flow through this matrix to be absorbed by an overlying dressing without adherence to the new epithelial surface.

Advantages/disadvantages

When in sheet form, these dressings can be cut and conformed to the shape of the wound. They are waterproof and adhere directly; as a result, they do not require a secondary dressing. In addition, these dressings have a cushioning or pressure-relieving effect (especially at bony sites), which increases as the dressing absorbs exudate. The resulting colloidal gel that forms prevents the dressing from adhering to the wound base. Accumulation of the exudate itself in a moist, semipermeable environment becomes a source of phagocytic cells and endogenous enzymes. This feature, along with the gel, results in autolytic debridement that can be washed away with saline irrigation of the wound bed[53]. Because hydrocolloids are impermeable to water, oxygen, and carbon dioxide, they are popular "waterproof" dressings[54].

Due to their semipermeable outer barrier, hydrocolloids have also been shown to stimulate angiogenesis and increase the rate of healing by as much as 40% when compared to open-air controls. A comparison of hydrocolloids versus wet-to-dry saline gauze dressings in the treatment of decubitus ulcers found that hydrocolloids do not require as many dressing changes as traditional wound dressings. Although the cost of individual hydrocolloid dressings was greater than gauze dressings and the healing rates were the same, the savings were in the cost of nursing time. In addition, the dressing changes tend to be simple and painless for the patient[55].

Disadvantages of hydrocolloids include maceration of the skin surrounding the wound, a potential for irritant or allergic contact dermatitis (e.g. to adhesives), and the risk of forming excessive granulation tissue. Similar to alginate dressings, the end product of hydrocolloids is a thick, yellow–brown, often foul-smelling gel resembling purulent discharge[56]. The patient needs to be educated regarding the distinction.

Downloaded for Anonymous User (n/a) at Egyptian Knowledge Bank from ClinicalKey.com by Elsevier on March 10, 2024. For personal use only. No other uses without permission. Copyright ©2024. Elsevier Inc. All rights reserved.

Superabsorbent Dressings

This expanding category of dressings is characterized by enhanced absorption, with exudate pulled up and often laterally into the construct of the dressing. By using a larger interface surface, more viscous drainage can be absorbed. Superabsorbent dressings contain particles composed of three-dimensional networks of polyacrylic acid polymers that are crosslinked by covalent bonds and swell upon contact with aqueous solutions. As water enters the dressing, the carboxylic acid groups of the polymer ionize and are electrostatically repelled from each other; this results in significant space for water and each particle can absorb hundreds of times its own weight in fluid. Superabsorbent dressings are indicated for exudative wounds and can also aid healing by trapping bacteria[57] and proteolytic enzymes[58]. If overlying pressure is placed (e.g. compression), it is important to remember that these dressings swell over time and this can increase pressure on the wound, potentially inhibiting healing[59].

Contact Layers

Contact layers are single-layer constructs that are applied directly to the wound surface. They are non-absorbent, non-adherent, woven polyethylene mesh dressings impregnated with different materials such as petrolatum, hydrocolloid, and silicone. These contact layers serve as primary dressings and are covered by a secondary dressing[60]. Wound exudate can flow through them while they protect the wound bed from the trauma of dressing changes. Contact layers are commonly used to secure and protect advanced tissue products (see below) and may stay in place for up to two weeks while the secondary dressings are changed more frequently.

Composite Dressings

The designs of occlusive dressings are constantly changing with the goal of improved and simplified care for a greater range of wounds. Several newer types of composite dressings, which combine two or more types of semi-occlusive dressings into one product, are commercially available. They have three components: (1) a semi- or non-adherent layer that contacts the wound (like a hydrogel, hydrocolloid, foam or alginate; Fig. 145.10); (2) an absorptive layer; and (3) an outer layer (like a film with an adhesive border). This maximizes the efficiency and comfort of the dressing by expanding absorbency as well as lessening the chance of maceration[61]. Other features include the lack of need for secondary retention dressings and better waterproof coverings, which enable the patient to shower or bathe.

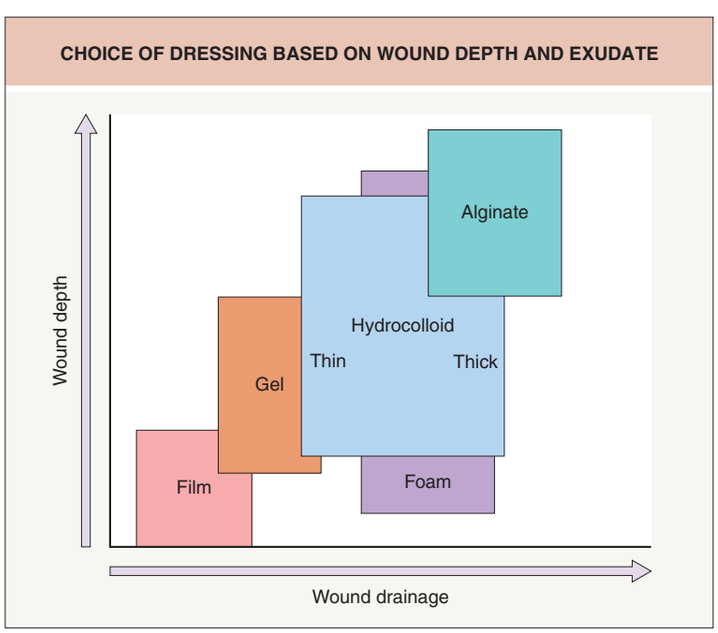

Fig. 145.10 Choice of dressing based on wound depth and exudate. *Courtesy Gregg M. Menaker, MD.*

ADVANCED WOUND THERAPIES

Scientific and clinical advances have increased the therapeutic options for chronic wounds. For example, topical growth factors and tissue-engineered skin equivalents can be combined with standard treatments[62–64].

Topical Growth Factors

Growth factors are critical to the wound healing process, as they stimulate fibroblasts, promote angiogenesis, and encourage migration of keratinocytes. Fluid from acute wounds contains multiple growth factors including platelet-derived growth factor (PDGF) and epidermal growth factor (EGF). Maintaining contact of this fluid with the underlying wound bed via the use of occlusive dressings has been shown to augment wound healing. A topical formulation of recombinant human PDGF, becaplermin (Regranex®) gel, has been shown to increase the complete closure rate of diabetic foot ulcers by 43%. Its current FDA indication is for non-healing diabetic neuropathic foot ulcers[65]. Unfortunately, *in vivo* results with other growth factors failed to translate into improved wound healing in human clinical trials, highlighting the complex microenvironment of a chronic wound.

Tissue-Engineered Skin Equivalents or Skin Substitutes

Advances during the 1970s in tissue culture techniques for keratinocytes and fibroblasts, including the ability to generate large quantities of these cells, resulted in the production of a new group of wound dressings. A variety of tissue-engineered skin equivalents, both cellular and acellular, are commercially available and Table 145.5 outlines some of these products. A true skin substitute provides both the physiologic and mechanical functions akin to an autologous skin graft. Advantages of tissue-engineered dressings include no painful donor sites and the potential for providing coverage of large areas.

Chronic wounds treated with engineered dressings often undergo an "edge effect", characterized by promotion of epithelialization from the edge of the ulcer toward its center, likely due to a release of cytokines by the donor cells[66]. There are currently three types of skin substitutes: epidermal grafts, dermal replacements (acellular or cellular), and composite grafts (with both an epidermal and dermal component). Tissue-engineered dressings can also be classified as autologous, allogeneic (human donor), or xenogeneic (usually bovine or porcine). Currently, the primary allogeneic sources are cadaveric dermis and neonatal foreskin. *Cellular and tissue-based products*, which includes skin equivalents and substitutes, is a term used by the FDA to signify those products regulated by the Center for Biologics Evaluation and Research.

Epidermal Grafts

The first cultured epidermal autografts were successfully cultivated in 1975 by Rheinwald and Green. They have been used successfully in a variety of clinical situations including burns, chronic ulcers, vitiligo, and postsurgical wounds.

Epicel® represents an epidermal autograft in which a skin biopsy is obtained from the patient and then the *autologous* keratinocytes are co-cultured with irradiated murine fibroblasts that serve as a feeder layer[67]. A sheet of keratinocytes two to eight cells thick forms and is attached to petrolatum gauze. The graft is then sutured in place and the gauze backing is removed at 1 week when the keratinocytes have attached to the wound. Skin biopsies obtained 6–12 months post-grafting show anchoring fibrils and neovascularization. This epidermal autograft is approved for use in partial- and full-thickness burns. Disadvantages include the several-week period required to culture the keratinocytes, graft fragility, a short shelf life, and the cost of processing.

For decades, the roofs of suction blisters created in uninvolved skin have been used to repigment vitiligo. More recently, an automated system for epidermal autologous grafting was introduced that uses heat and suction to produce small epidermal microdomes, with consistent cleavage at the lamina lucida[68]. Advantages include no requirement for anesthesia or a highly skilled surgeon, performance in an outpatient setting, minimal donor site pain, and lack of scarring. The grafts have been applied to a variety of chronic and acute wounds and pathergy has not been observed in patients with pyoderma gangrenosum.

Downloaded for Anonymous User (n/a) at Egyptian Knowledge Bank from ClinicalKey.com by Elsevier on March 10, 2024. For personal use only. No other uses without permission. Copyright ©2024. Elsevier Inc. All rights reserved.

TISSUE-ENGINEERED SKIN EQUIVALENTS			
Examples (name and description)	**Possible uses**	**Advantages**	**Disadvantages**
Single layer – viable cells			
Autologous			
Epicel® – sheet of cultured **keratinocytes** (derived from a skin biopsy) attached to petrolatum gauze [commercially available, FDA-approved for burns ≥30% BSA]	Partial- and full-thickness burns, congenital melanocytic nevus excision sites, pyoderma gangrenosum (non-inflammatory; see Ch. 26)	• Small donor site wound • Capable of self-repair • Single application is often sufficient • Permanent and cosmetically acceptable • Good adherence	• Very expensive • Minimal shelf life; must be used soon after delivery from manufacturer • Several-week culture period • Needs biopsy of normal skin • Contraindicated if history of anaphylaxis due to vancomycin, amikacin, or amphotericin
Allogeneic			
Dermagraft® – neonatal foreskin **fibroblasts** grown on a biodegradable mesh; FDA-approved for diabetic foot ulcers (see Table 145.6)	Diabetic foot ulcers	High level of evidence for effectiveness	• Fragile construct – sensitive to physical manipulation
Single layer – acellular or non-viable cells			
Xenogeneic (see Table 145.6 for additional information)			
Porcine collagen			
Oasis® Wound Matrix, Ultra Tri-Layer Matrix – porcine intestinal collagen type I and extracellular matrix (Fig. 145.11)	Chronic ulcers, including diabetic and venous, burns, skin tears, split-thickness graft donor sites, post-laser resurfacing	• Long shelf life* • Non-human origin avoids human pathogen transmission* • Immediately available* • Reduces pain of some wounds* • Stored at room temperature	• Expensive* • May adhere to wound strongly enough to damage new epithelium • Usually needs multiple applications • May have higher infection rate
Permacol® – acellular porcine dermal collagen (approved as surgical implant)	Used primarily for surgical repairs, e.g. abdominal, hernia	Stored at room temperature	
Biobrane® – acellular porcine collagen type I		Stored at room temperature	
Bovine collagen			
INTEGRA® Dermal Regeneration Template – bovine tendon collagen and shark chondroitin	FDA-approved for burns and diabetic foot ulcers	• High level of evidence of effectiveness for diabetic foot ulcers • Stored at room temperature • Flexible	• Possible bovine allergy
Matriderm® – bovine collagen types I, III and V plus solubilized elastin		• Stored at room temperature • Flexible	• Possible bovine allergy
Allogeneic (see Table 145.6 for additional information)			
AlloDerm® Regenerative Tissue Matrix, GRAFTJACKET NOW™ Acellular Dermal Matrix – cadaveric decellularized dermis	Burns and split-thickness skin graft sites	• Decreased pain • Immediate availability • Single application	• Theoretical risk of transmission of human pathogens
Human amniotic membrane (HAM) – inner layer of the amniotic sac	Diabetic foot ulcers	• Non-immunogenic • Applied without immobilization • Long shelf life (cryopreserved)	• Does not survive in chronic wounds after 2–4 weeks
Composite – cellular			
Xenogeneic & allogeneic			
Apligraf® – neonatal foreskin keratinocytes and fibroblasts plus bovine collagen type I; bilayered; FDA-approved for venous ulcers and diabetic foot ulcers	Diabetic foot ulcers (>6 weeks) and venous ulcers (>4 weeks) Epidermolysis bullosa	• High level of evidence • Self-repair ability • Single application (can be repeated up to 5 times) • Stored at room temperature • Immediately available (no several-week culture period as with autologous keratinocyte products)	• Several-week shelf life • Possible transmission of infectious diseases because of human donors but sources are screened
StrataGraft® – cultured human keratinocytes (NIKS cells) and dermal fibroblasts in murine collagen; FDA approved for deep partial-thickness burns	Deep partial- and full-thickness burns, chronic non-healing ulcers	• Promotes self-repair • Single application may be sufficient • Immediately available • Long shelf life (can be cryopreserved)	• Expensive • Avoid in patients with glycerin intolerance • Possible transmission of infectious diseases because of human donors but sources are screened
*Applies to all xenogeneic products.			

Table 145.5 Tissue-engineered skin equivalents. BSA, body surface area; min, minutes; NIKS cells, spontaneously immortalized human keratinocyte cell line. From refs 46, 56, 58, 60, 61, 63, e4–e6.

Downloaded for Anonymous User (n/a) at Egyptian Knowledge Bank from ClinicalKey.com by Elsevier on March 10, 2024. For personal use only. No other uses without permission. Copyright ©2024. Elsevier Inc. All rights reserved.

Dermal Replacements

There are two types of dermal replacements: xenogeneic and allogeneic (Table 145.6). Neither of these is permanent: DNA analysis of wounds after the application of non-autologous skin substitutes shows almost complete disappearance of the grafted cells after two months[69]. The goal of these dermal grafts is to provide a temporary biologic scaffold in order to stimulate the healing process. They are placed over the wound, extending slightly onto normal skin, and then bolstered into place. Secondary dressings must be applied. It is advisable to keep the primary dressing in place for up to a week following its placement and to follow the individualized product instructions. The major component of dermal replacements is collagen; other elements of the extracellular matrix, e.g. glycosaminoglycans (GAGs), may be included and in the case of cellular products, fibroblasts.

Xenogeneic

Although other sources are available, xenogeneic grafts are usually composed of porcine or bovine collagen (see Table 145.6). The advantages of these products are: (1) their ability to effect hemostasis and to provide immediate closure as well as cosmetically acceptable scars with second intention healing; (2) safety from potential human pathogen transmission due to their animal origin; and (3) an adequate shelf life, facilitating off-the-shelf access.

Oasis® Wound Matrix and Biobrane® are examples of acellular matrices derived from porcine collagen (Fig. 145.11). They have significant elasticity, enabling a full range of motion of the covered body part, and there is no requirement for dressing changes once it has adhered to the wound bed. However, Biobrane® may adhere to the wound so tightly that it can damage newly developed epithelium[70].

INTEGRA® Dermal Regeneration Template is composed of two layers: an outer silicone layer overlies a layer composed of bovine tendon

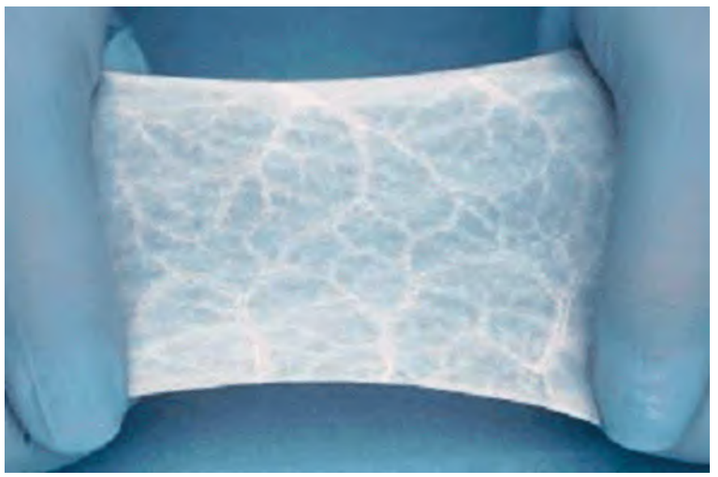

Fig. 145.11 An acellular xenogeneic dressing. This particular wound matrix is derived from porcine small intestine submucosa (Oasis®) and serves as a dermal graft.

SELECTED DERMAL REPLACEMENT GRAFTS		
	Description	**Comments**
Xenogeneic		
Biobrane®	Bilayer dressing: inner nylon mesh fabric coated with **porcine** type I collagen ("dermis") bonded to a semipermeable silicone film membrane ("epidermis")	• Tissue ingrowth into the nylon fabric following binding of collagen to fibrin • Trilaminar nylon (better for clean, partial-thickness burn wounds or donor sites) and monofilament nylon (better for meshed autografts) • Approved for partial-thickness burns
Oasis® Wound Matrix, Ultra Tri-Layer Matrix	Derived from porcine small intestine submucosa (mucosa and muscle removed) **Porcine** type I collagen, extracellular matrix (e.g. hyaluronic acid, fibronectin), and growth factors (FGF, TGF-β)	• In study of 120 patients with venous leg ulcers, after 12 weeks of treatment, 55% of Oasis® + compression group healed vs 34% in compression alone group; at 6 months, 100% and 70% remained healed, respectively • Approved for venous, diabetic and pressure ulcers, second-degree burns, graft donor sites, surgical wounds, and full-thickness skin injuries
INTEGRA® Dermal Regeneration Template	Bilayer dressing: **bovine** tendon collagen admixed with **shark** cartilage-derived, modified GAGs ("dermis") plus an outer silicone membrane	• Debridement required prior to graft placement with sutures or staples • Outer silicone cover removed after several weeks; in large wounds, replaced by ultrathin autograft (two-step process) • In a controlled trial of diabetic foot ulcers, improved time and rate of wound closure when compared to standard of care treatment • Approved for life-threatening third-degree burns and diabetic ulcers
Allogeneic		
AlloDerm® Regenerative Tissue Matrix*	Human cadaveric skin, chemically treated and purified to remove epidermis, all cellular components, and pathogens Cryopreserved (shelf life of 6 months)	• Repopulation of host fibroblasts and endothelial cells seen within 10 days of grafting • Approved for repair or replacement of damaged or inadequate integumental tissue, e.g. breast reconstruction
Dermagraft®	Neonatal foreskin fibroblasts are seeded onto a 3-D scaffold of biodegradable polyglactin mesh	• Similar time to graft take and similar fibroblast function as TransCyte™ (see below) • In 245 patients with diabetic ulcers, significant improvement in wound closure by week 12: Dermagraft® 30% versus conventional therapy 18% • Approved for full-thickness diabetic foot ulcers present >6 weeks that are deep but do not involve tendons, muscle or bone; HDE for ulcers in epidermolysis bullosa
Xenogeneic & allogeneic		
Transcyte™	Biobrane® (see above) plus neonatal foreskin fibroblasts	• Requires ~2 weeks for graft take • Fibroblasts initially secrete extracellular matrix (including collagen) and growth factors that stimulate granulation tissue and epithelialization but then die • In a controlled trial of excised burns, easier to use and similar outcomes when compared to human cadaveric skin • Approved for deep partial- and full-thickness burns

*Additional allogeneic grafts include those derived from human umbilical cord (EpiCord®) and placental membranes (AmnioBand® EpiFix™, Grafix®, NuShield®). Other acellular dermal matrices (ADMs) that may be used for venous and diabetic ulcers as well as breast reconstruction include AlloMax™, AlloPatch®, DermACELL™, DermaMatrix™, Flex HD®, Strattice™, SurgiMend®, and TheraSkin®.

Table 145.6 Selected dermal replacement grafts. FGF, fibroblast growth factor; GAGs, glycosaminoglycans; HDE, humanitarian device exemption; TGF-β, transforming growth factor-β. *From refs 46, 57, 60, 61, 63, e4–e11. Courtesy Gregg M. Menaker, MD.*

Downloaded for Anonymous User (n/a) at Egyptian Knowledge Bank from ClinicalKey.com by Elsevier on March 10, 2024. For personal use only. No other uses without permission. Copyright ©2024. Elsevier Inc. All rights reserved.

collagen and shark cartilage GAGs. The latter is thought to simulate dermal matrix. Because INTEGRA® has a complicated application procedure, the FDA requires that all physicians complete a company-sponsored training program.

Allogeneic

Allogeneic dermal grafts are composed of cadaveric dermis or neonatal foreskin fibroblasts (see Table 145.6). The advantages of these products include their ability to provide immediate closure and cosmetically acceptable scars with second intention healing, in addition to an adequate shelf life, facilitating off-the-shelf access. However, there is a risk of graft rejection due to T cell recognition of donor T cells[71]. Examples include AlloDerm® Regenerative Tissue Matrix which consists of decellularized cadaveric dermis and GRAFTJACKET NOW™ Acellular Dermal Matrix which is derived from processed acellular cadaveric skin (see Table 145.5). The FDA currently categorizes both AlloDerm® and GRAFTJACKET NOW™ as banked human tissue for transplantation. Dermagraft® is a biodegradable scaffold seeded with neonatal foreskin fibroblasts and is FDA-approved for the treatment of diabetic foot ulcers[72].

Composite Grafts

Engineered composite grafts are bilayered skin equivalents. Current products consist of an epidermal layer composed of human keratinocytes and a dermal layer composed of bovine collagen matrix seeded with human fibroblasts. In Apligraf®, both cell types are derived from human neonatal foreskins (Fig. 145.12). This composite graft produces its own matrix proteins and growth factors and, if wounded, it can repair itself. Although FDA-approved for venous leg ulcers and diabetic foot ulcers, Apligraf® has been used to treat acute and chronic wounds that failed to heal by standard means, including those due to epidermolysis bullosa, pyoderma gangrenosum, burns, and surgical excisions. Whereas several applications of the material may be required to completely heal chronic wounds, a single application may be sufficient to initiate a satisfactory healing response. Chronic venous ulcers that were randomized to receive compression plus Apligraf® healed in a shorter time period compared to compression alone, especially in the case of larger defects[72,73].

More recent evidence suggests that Apligraf® modulates an array of cellular pathways in the epidermis at the wound's edge, ultimately transforming a chronic wound into an acute one[74]. In venous leg ulcers, Apligraf® also stimulates antifibrotic changes within the wound bed[75]. This includes decreased expression of gene targets of profibrotic TGF-β1, increased levels of the TGF-β inhibitor decorin, and upregulation of fibroblast-derived matrix metallopeptidase 8.

A point-of-care delivery system named RECELL® was recently developed that allows delivery of autologous skin to the wound bed via a cell spray containing keratinocytes, melanocytes, Langerhan cells, and papillary dermal fibroblasts[76]. This onsite cell harvesting device can create 1 ml of cell suspension from a 1 cm^2 piece of split-thickness donor tissue; the former can then be sprayed onto an area of up to 80 cm^2. The maximum per device is 24 ml of cell suspension. In a randomized controlled study in burn patients that compared standard split-thickness skin grafts (STSGs) versus the application of RECELL® Spray-On Skin™ cells to widely meshed STSGs, the cell spray had similar efficacy and safety but decreased the donor site area by ~30%[77].

Apligraf® and similar products are costly, but they have an excellent safety profile as well as the advantage of accelerating healing and reducing long-term costs.

Negative Pressure Wound Therapy (NPWT)

NPWT, developed in the 1990s, is based on the delivery of sub-atmospheric pressure to the wound bed. In this vacuum-assisted closure (VAC) system, a polyurethane or polyvinyl alcohol foam is cut and placed on the wound surface. The foam is then sealed over by a transparent drape in order to provide a closed airtight system (Fig. 145.13). A vacuum pump, connected to this space via a plastic tube, provides a negative pressure environment. NPWT removes interstitial fluid, stimulates angiogenesis, and enhances circulation as well as lymphatic drainage. There is evidence to support the use of NPWT for acute postsurgical wounds[78]. Although there is some evidence that NPWT improves healing of diabetic foot ulcers, more information regarding appropriate patient selection, duration of treatment, and use of combined treatments is required[79].

Nowadays there are portable, often single-use, systems that can deliver effective negative pressure to a variety of low-to-moderately exudative wounds. Some of these systems use superabsorbent dressings, rather than a canister, to retain wound exudate[80]. The dressing is placed under a sealed film covering and is linked to a battery-operated, portable pump that can be harnessed around the thigh, allowing for patient mobility[80]. Single-use NPWT systems appear to lead to similar, if not improved, wound healing and they reduce the cost of care given the outpatient setting[81]. Another modification is lavage of the wound bed by a wound cleanser or antiseptic while the NPWT is functioning[82].

Oxygen Therapy

Because multiple studies have pointed to hypoxia as one of the major factors leading to a delay in wound healing, both hyperbaric oxygen therapy (HBOT) and topical oxygen therapy have been utilized.

Fig. 145.12 Example of an engineered composite (xenogeneic and allogeneic) graft sutured into place (Apligraf®). *Courtesy Gregg M. Menaker, MD.*

Fig. 145.13 Negative pressure wound therapy. In negative pressure wound therapy, a polyurethane (this patient) or polyvinyl alcohol foam is cut and placed on the wound surface. The foam is then sealed over by a transparent drape. A vacuum pump, connected via a plastic tube, provides a negative pressure environment. The sterile polyurethane foam has large pores and stimulates granulation tissue.

Downloaded for Anonymous User (n/a) at Egyptian Knowledge Bank from ClinicalKey.com by Elsevier on March 10, 2024. For personal use only. No other uses without permission. Copyright ©2024. Elsevier Inc. All rights reserved.

In HBOT, oxygen is administered at pressures greater than one atmosphere. Patients are placed in a pressure chamber where they breathe oxygen at this increased pressure. Systemic HBOT sessions last 45–120 minutes and are conducted once or twice daily for 20–30 sessions. This oxygenation of hypoxic tissue induces vasoconstriction and reduces edema and congestion. At a cellular level, there is increased fibroblast replication, collagen synthesis, and neovascularization as well as upregulation of growth factors.

To screen for a potential response to HBOT, the patient has transcutaneous oxygen levels measured in the peri-wound region both at baseline and while breathing 100% oxygen; at least a doubling of the levels is preferred. While a systematic review concluded that there was short-term but not long-term improvement of diabetic ulcers with HBOT[83], randomized controlled trials with small sample sizes reported the effectiveness of HBOT[84]. A data analysis of 6259 patients did not support the use of HBOT for diabetic foot ulcers, highlighting the need for large randomized controlled trials[85]. Additional methods for oxygenation of wounds include topical pressurized oxygen, topical continuous diffusion of oxygen, and dressings that release oxygen, but proper selective application of these interventions is required[86].

COMPRESSION THERAPY

Based on substantial scientific and clinical evidence, compression therapy represents the mainstay of treatment for all cutaneous manifestations of chronic venous insufficiency, from varicose veins and edema to lipodermatosclerosis and venous leg ulcers. The physiologic effects of compression include acceleration of the velocity of venous flow, augmentation of venous return toward the heart, reduction of venous reflux and edema, promotion of oxygenation to the surrounding dermis, and stimulation of fibrinolysis[87]. Compression therapy is also employed following lower extremity surgical procedures.

Types of Compression

There are several different methods of compression therapy, ranging from stockings and compression bandages to devices such as intermittent pneumatic compression systems (Table 145.7). Compression stockings are graded from Class I to IV based upon the pressure at the ankle (see Table 105.4) whereas compression bandages are classified as either long stretch (elastic with substantial extensibility) or short stretch (inelastic with limited extensibility). Multiple factors influence the sub-bandage pressure including: (1) the tension or amount of force that is used to stretch the bandage during application; (2) the width of the bandage – wider bandages are associated with decreased compression; (3) the size of the leg – a larger circumference leads to reduced pressure; and (4) the number of layers of compression – a higher number increases pressure[88]. This is reflected in a modified Laplace law[89]:

$$\text{Sub-bandage pressure (mmHg)} = \frac{\text{tension (KgF)} \times \text{number of layers} \times \text{a constant}}{\text{limb circumference (cm)} \times \text{bandage width (cm)}}$$

In addition to the type of bandage material and the method of wrapping, the amount of pressure also depends on muscle contraction.

Although the definitive optimal pressure required to prevent capillary leakage secondary to venous hypertension has not been delineated, an ankle pressure of 30–40 mmHg is recommended for leg ulcers[90]. The higher compression pressure of 40 mmHg should be considered for persons with an ankle–brachial index (ABI) of 0.8 to 1.3, indicating adequate vascular supply (see Table 105.8). In patients with predominantly venous disease, but coexisting arterial compromise (ABI = 0.66–0.8), modifications in the form of inelastic (rather than elastic) compression and fewer layers of compression is recommended[91,92]. Individuals with an ABI of 0.5 to 0.65 should have further modifications, e.g. one or two layers of a tubular bandage that can be easily removed. Inappropriate compression bandaging in patients with arterial disease can lead to ischemia and is therefore potentially harmful. Patients with congestive heart failure (CHF) may have difficulty tolerating compression therapy because compression of the lower extremities may increase preload volume and worsen CHF.

Compression stockings

With graduated compression stockings, the patient is afforded some independence in the application of the device. However, for arthritic

TYPES OF COMPRESSION SYSTEMS			
Compression system	**Examples**	**Advantages**	**Disadvantages**
Long stretch (elastic) bandages	ACE™, Biflex® (also short), Dauerbinde® K, SurePress®	• Base of the toes to knees • Low working pressure • High resting pressure • 100%–200% extensibility • Can be applied as spiral or figure-of-eight • Inexpensive; washable and reusable forms available	• Tend to unravel • Do not provide a sustained compression • Risk of incorrect application • Can lose elasticity with continued use
Short stretch (inelastic) bandages	Zinc paste (Viscopaste®/Unna boot), Actio®, Biflex® (also long), Comprilan®, Panelast®, Porelast®	• Comfortable so better tolerated • Minimal interference with daily activities • Some (e.g. Viscopaste®) can generate high working pressure	• Can lose compression after application • Not good for highly exudative wounds • Viscopaste®/Unna boot needs to be applied by well-trained staff
Devices	CircAid® (with Velcro®), FarrowWrap® (with Velcro®), Sigvaris CoolFLEX® (with metal fastening clasps)	• Adjustable compression • Easy to put on and remove	• Expensive • Bulky
Multicomponent bandages	Coban™ 2, Coban™ 2 Lite, Profore® (5 layers), Profore® Lite (4 layers), Actico®2 C	• Higher compression and sustained high compression • Graduated compression • Reduced ("Lite") compression available for patients with mixed venous and arterial disease	• Needs to be applied by well-trained staff
Intermittent compression devices	Lympha Press® (pneumatic pump)	• Enhance fibrinolytic activity	• Expensive • Requires being immobile for a few hours per day
Tubular system	Tubigrip® (contains latex) EdemaWear® Medigrip LF™	• Easy to use • Tubular bandage doubled back over limb to increase compression	• Low compression (unless that is what is desired because of coexisting arterial disease)

Table 145.7 Types of compression systems. LF, latex free. From refs 70, 73, 83, e12–e14.

Downloaded for Anonymous User (n/a) at Egyptian Knowledge Bank from ClinicalKey.com by Elsevier on March 10, 2024. For personal use only. No other uses without permission. Copyright ©2024. Elsevier Inc. All rights reserved.

Fig. 145.14 Unna boot. Non-elastic compression therapy with a zinc-impregnated compression wrap.

and/or elderly patients, application can be difficult unless the stockings have zippers or Velcro® fasteners. Although compression stockings are commonly used as maintenance therapy, recent studies have observed that they are comparable to bandaging systems for the treatment of venous leg ulcers, including producing similar healing rates[93]. A systematic review found no significant differences between compression stockings and compression bandages with respect to ulcer healing, time to ulcer healing, or ulcer recurrence[94]. In general, compression stockings are more tolerable, less costly, and less bulky. Patient education and demonstration can lead to increased compliance.

Compression bandages

In the 1880s, Paul Gerson Unna introduced a bandage, now referred to as the Unna boot, for the treatment of venous leg ulcers and selected eczematous dermatoses. It was originally a cotton bandage impregnated with zinc oxide, gelatin, and glycerin paste. Applied in a semi-rigid state, the Unna boot confers (semi-rigid) compression, along with the advantages of a moisture-retaining occlusive dressing (Fig. 145.14). It should be applied by a qualified medical professional and changed once a week unless heavy drainage from the wound necessitates more frequent replacement. Correct application of the Unna boot prevents excessive or abnormal pressure to the limb, compromised circulation, skin breakdown, additional ulcer formation, or further limb deterioration (Video 145.1). Over a century later, the Unna boot is still a frequently employed compression bandage for venous leg ulcers[95].

Medicated paste bandages such as the Unna boot can be used alone (inelastic) or underneath an additional layer of cohesive bandaging (e.g. Coban™ [elastic]), especially on the lower extremities. By creating an absorptive, protective contact layer, they can also address the stasis dermatitis often associated with leg ulcers. In addition to preservatives, these open-weave cotton bandages are impregnated with: (1) zinc oxide paste, calamine, or ichthammol, all of which have a soothing action on irritated skin; (2) coal tar, which has an anti-inflammatory effect; or (3) clioquinol, which has deodorizing and antibacterial actions. Preservative-free zinc oxide products are commercially available as are combinations of zinc oxide with each of the above components or calamine plus clioquinol.

Short stretch (inelastic) versus long stretch (elastic) bandages

Elastic bandages provide both easy stretchability and a sustained squeeze on tissue (see Table 145.7). This is because these bandages recoil back to their original length due to the presence of elastomeric fibers. In contrast, inelastic bandages such as the Unna boot and short stretch bandage (more commonly used in Europe) form a rigid covering that resists lateral expansion of the calf muscle during active contractions. Of note, contractions of the calf muscle act as a pump that generates a propelling force to promote venous return (see Fig. 105.2).

Compression bandages may be composed of a single component or multiple combined components. In a meta-analysis[96], short stretch bandages were found to be as efficacious in promoting healing of venous leg ulcers as more complex multi-component bandaging systems, in both ambulatory and non-ambulatory patients. However, Cochrane reviews suggest that the evidence supports multi-component systems (over single-component systems) and systems with an elastic component (over those with an inelastic bandage)[97]. Lastly, tubular systems (Tubigrip®, EdemaWear®) provide low compression and can be used by patients with reduced ABIs (see above).

Compression devices

Intermittent pneumatic compression (IPC) devices deliver sequential pressure to the limb. IPC is a beneficial adjunct to other forms of compression in the treatment of venous leg ulcers, especially for non-ambulatory patients[98,99]. When the calf muscle pump is not active, the use of a dynamic compression system is more beneficial than a passive system[99–101]. Portable IPC devices that are relatively easy to operate are available for home use. In a randomized controlled trial, patients with lymphedema and venous leg ulcers healed faster and with less pain when a 4-layer compression system was combined with daily home-based IPC as compared to 4-layer compression alone[102]. Both self-adjustable Velcro® devices and hybrid systems are alternative compression therapy choices that may increase compliance.

FUTURE DIRECTIONS

Wound dressings are an essential component of wound care, compression therapy for venous leg ulcers, and pressure redistribution for pressure ulcers. Over the past century, dressings have moved from a passive to more active role with improvements in moisture-retentive products and delivery systems. However, incorporation of active ingredients into traditional dressings increases their cost and raises regulatory issues as to whether a dressing is a drug or a medical device. Advances based on growth factors, cellular therapy, and skin substitutes will continue, but selection of the most appropriate dressing for a given clinical scenario will remain the key decision for the physician.

Additional figures and references available in our eBook (see inside front cover for access code).

eFig. 145.1 Activated charcoal cloth impregnated with silver (Actisorb® Silver 220). The envelope is spun bonded nylon.

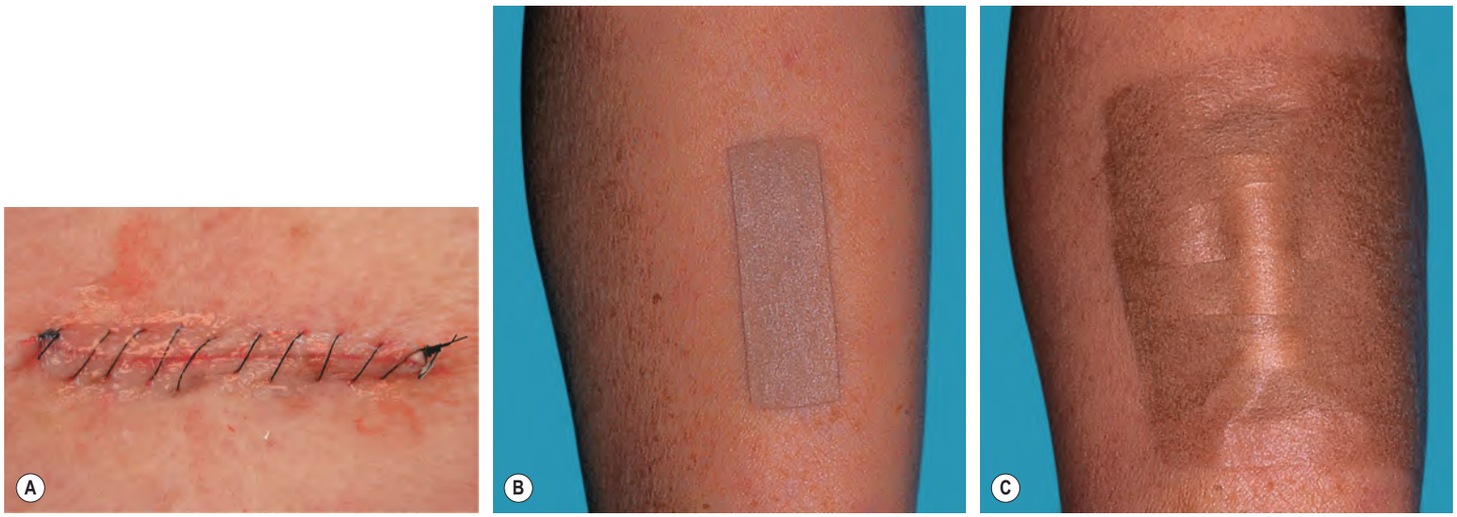

eFig. 145.2 Pressure dressing. A Ointment applied over sutures to prevent the contact layer from adhering directly to the wound. **B** Three layers of paper tape comprise the contact layer. **C** Rolled gauze or a cotton dental roll can be used to: (i) provide pressure for hemostasis; (ii) aid in conforming the dressing to the wound; and (iii) absorb excess exudate. The entire dressing is secured with additional layers of tape. *Courtesy Gregg M. Menaker, MD*.

eFig. 145.3 A polymer film is used to occlude a wound that has been covered by cotton gauze. *Courtesy Gregg M. Menaker, MD*.

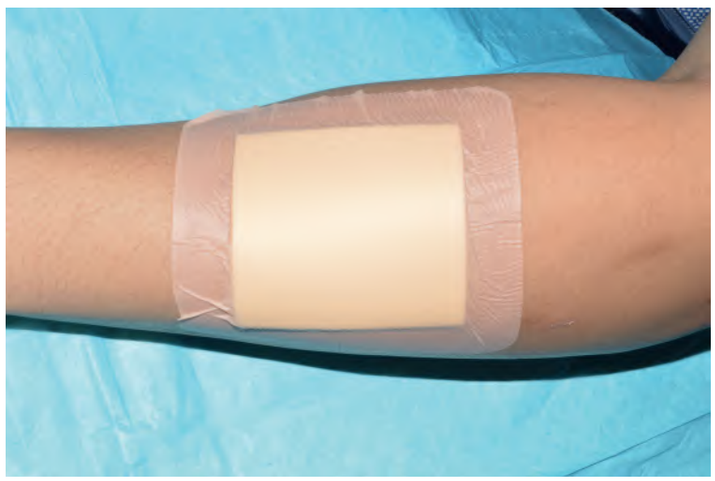

eFig. 145.4 A foam dressing.

Downloaded for Anonymous User (n/a) at Egyptian Knowledge Bank from ClinicalKey.com by Elsevier on March 10, 2024. For personal use only. No other uses without permission. Copyright ©2024. Elsevier Inc. All rights reserved.

eFig. 145.5 Occlusive dressings for post-laser resurfacing. A In this side-by-side comparison, the patient's left face is dressed with a foam dressing. **B** In this side-by-side comparison, the patient's right face is dressed using the open technique.

eFig. 145.6 Example of an alginate.

eFig. 145.8 Graduated compression stockings being applied.

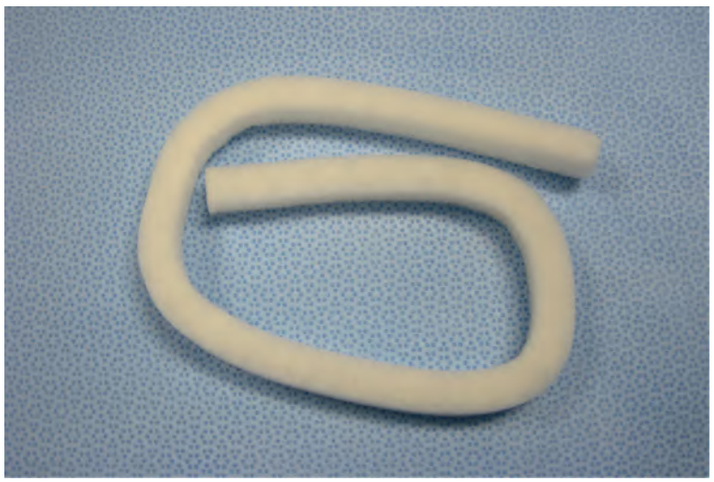

eFig. 145.7 Example of a collagen–alginate complex dressing. The rope form can be used to pack deep wounds. *Courtesy Gregg M. Menaker, MD*.

Video 145.1 Unna Boot Dressing.

Downloaded for Anonymous User (n/a) at Egyptian Knowledge Bank from ClinicalKey.com by Elsevier on March 10, 2024. For personal use only. No other uses without permission. Copyright ©2024. Elsevier Inc. All rights reserved.